



Republic of the Philippines
Department of Education
REGION III
SCHOOLS DIVISION OF PAMPANGA

Advisory No. 052, s. 2025

July 07, 2025

In compliance with DepEd Order (DO) No. 8, s. 2013
this advisory is issued not for endorsement per DO 28, s. 2001,
but only for the information of DepEd officials,
personnel/staff, as well as the concerned public.

**VOLUNTARY FINANCIAL ASSISTANCE FOR MS. IRENE M. DE GUZMAN
TEACHER III, PLANAS ELEMENTARY SCHOOL,
PORAC WEST DISTRICT,
SCHOOLS DIVISION OFFICE OF PAMPANGA**

We sincerely empathize with the medical condition of Ms. Irene M. De Guzman, Teacher III at Planas Elementary School, Porac West District, Schools Division Office of Pampanga, who is currently in critical health and in need of financial assistance. She was diagnosed with a Cerebellopontine Angle Tumor and has been hospitalized since June 24, 2025. She underwent two surgeries, on June 25 and July 3, 2025, and remains confined in the Intensive Care Unit (ICU) while continuing to receive medication and treatment.

The assistance she will receive will be used to help settle her medical expenses and purchase necessary medications. Attached are relevant documents including medical records for reference.

Your voluntary financial assistance will be of great help in alleviating her family's financial burden. Donations may be sent through the following G-Cash accounts:

G-Cash

Account Name: **IRENE M. DE GUZMAN**

Account Number: 0920-578-8019

Account Name: **MARIBEL M. SERRANO**

Account Number: 0919-492-1660

For information and dissemination.



July 05, 2025

ROMEO M. ALIP, PhD, CESO V
Schools Division Superintendent
Division of Pampanga
City of San Fernando (P)

Sir:

Greetings of peace!


I, Jonel S. Malig am respectfully seeking financial assistance for my sister, **Irene M. De Guzman**, Teacher III of Planas Elementary School.

She has been hospitalized since June 24, 2025, due to a **Cerebellopontine Angle Tumor**. She underwent two surgeries, on June 25 and July 3, 2025. At present, she remains confined in the Intensive Care Unit and continues to receive medications. We are still uncertain as to when she will be able to return to work.

I sincerely hope for your kind consideration and support during this difficult time.

Thank you very much, and may the Lord Almighty bless your generous hearts.

Respectfully yours,


JONEL S. MALIG
Brother

Gcash Details
0920-5788-019
Irene M. De Guzman

0919-4921-660
Maribel M. Serrano



Republic of the Philippines
Department of Education
REGION III
SCHOOLS DIVISION OF PAMPANGA
PORAC WEST DISTRICT
PLANAS ELEMENTARY SCHOOL

ROMEO M. ALIP, PhD, CESO V


Schools Division Superintendent

Division of Pampanga

City of San Fernando (P)

00014144

ATTENTION: JB B. MANALANG
ADMINISTRATIVE OFFICER V



Sir:

This is to submit to your good office the request for Voluntary Financial Assistance for **MS. IRENE M. DE GUZMAN**, Teacher III from Planas Elementary School, Porac West District.

Very truly yours,

Signature
MARY GRACE B. GAMBOA
PRINCIPAL II



Republic of the Philippines
Department of Education
REGION III
SCHOOLS DIVISION OF PAMPANGA
PORAC WEST DISTRICT
PLANAS ELEMENTARY SCHOOL

May 26, 2025

ROMEO M. ALIP, PhD, CESO V
Schools Division Superintendent
Division of Pampanga
City of San Fernando (P)

Sir:

Greetings of peace!

I, Mary Grace B. Gamboa, School Head of Planas Elementary School, Porac West District is asking your good office for financial assistance for my teacher, **Irene M. De Guzman**, Teacher III of the above-mentioned school for she was hospitalized last April 05, 2025 to April 12, 2025 and diagnosed with Cerebellopontine Angle Tumor and has to undergo a procedure which cost 650,000php alone aside from the medications she has gone through prior to the said operation.

At this moment, they are financially challenged. She is still currently taking medications and seeking for monetary assistance to fund her operation.

Thank you very much and may the Lord Almighty bless each one of your generous hearts.

Very truly yours,

Mary Grace B. Gamboa
MARY GRACE B. GAMBOA
PRINCIPAL II

ST. CATHERINE OF ALEXANDRIA FOUDATION AND MEDICAL CENTER, INC.

Lot 5-6 Block 13 Rizal Extension, Brgy. Cutcut, Angeles City 2009 Philippines
Mobile Numbers: 0918-948-1097(Smart)/0917-514-2455(Globe)/0322-831-6876(Sun)
Email Address: medrec.scfmc@gmail.com

"We Serve, We Care, We Share, Committed to Provide Quality Health Care Service."

MEDICAL CERTIFICATE

Date: **MAY 22, 2025**

TO WHOM IT MAY CONCERN:

This is to certify that **IRENE M. DE GUZMAN**

43 YEARS OLD/FEMALE/CHILD

a resident of **BLOCK 15 LOT 91 MODEL COMMUNITY, PIO, PORAC, PAMPANGA**

was treated in this hospital during the following dates **APRIL 05, 2025 TO APRIL 12, 2025**

Diagnosis:

CEREBELLOPONTINE ANGLE TUMOR

Operation/s:

N/A

Remarks:

N/A

This certification is issued upon the request of

IRENE M. DE GUZMAN

for the purpose of

FINANCIAL ASSISTANCE

SIGNED:

CASIÑO, DOMINGO REGINO M.D. / BOGNOT, RONA R. M.D.

Attending Physician

PRC License No. **0085878/0124209**

CERTIFICATE NO. **IPD00004285**



NOT VALID WITHOUT DRY SEAL



**Our Lady of
Mt. Carmel**
Medical Center
Experience Divine Medical Care



patientrelations.csfp@olmc.mc.com



(045) 845 6202
(0918) 9398524

SECTION OF MAGNETIC RESONANCE IMAGING

NAME	DE GUZMAN, IRENE	CASE NO.	
AGE/SEX	43 YEARS OLD/ FEMALE	DATE	04/08/2025
PROCEDURE	CRANIAL MRI WITH CONTRAST	PHYSICIAN	DR. PAMINTUAN

HISTORY: headache, dizziness, rule out tumor vs stroke

TECHNIQUE: Non-contrast and contrast-enhanced MRI of the BRAIN in multiplanar views

FINDINGS:

Lesion: A 3.1 x 4.1 x 2.6 cm (AP x T x CC) predominantly T1-hypo/ T2-hyperintense and heterogeneously-enhancing extra-axial focus is seen in the left cerebello-pontine angle with involvement of the widened left internal auditory meatus /VII-VIII cranial nerve complex. Fluid signals are noted within the lesion, may represent cystic spaces. Areas of susceptibility signals are also evident within the lesion due to old blood products. Minimal perilesional edema is noted. It compresses the left cerebellar hemisphere posteriorly and slightly compresses the pons medially. The left cisternal trigeminal nerve is also compressed. The mass is abutting the cranial nerves emanating from the left side of the medulla.

Ventricular system: compression of the fourth ventricle resulting to mild to moderate supratentorial hydrocephalus

Intracranial hemorrhage: No intra-axial hemorrhages

Brain parenchyma:

1. No acute infarct
2. Minimal white matter bright signals in the periventricular regions due to early arteriolosclerosis or areas of demyelination.
3. Mild diffuse parenchymal volume loss.

Brainstem/Cerebellum/right CP angle/Sella-Suprasella/Cavernous sinus: Unremarkable

Paranasal sinuses/ Mastoid air cells/Nasal/Nasopharynx/Orbits/Cranio-cervical: Mild left maxillary sinus disease with retention cysts are noted, measuring up to 1.9 cm.

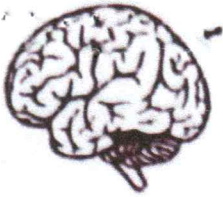Calvarium/skull base/soft tissues: unremarkable

IMPRESSION:

1. Left posterior fossa mass in the CP angle, as discussed. Primary consideration is a SCHWANOMMA
2. Minimal white matter signals in the bilateral periventricular region, may be due to early arteriolosclerosis or areas of demyelination; Interval demonstration of faint small hypodensity in the left corona radiata suggestive of acute infarct.
3. Mild cerebral and cerebellar volume loss
4. Mild left maxillary sinus disease with retention cysts

Dear Doctor, thank you for your referral.

IRMA D. DAVID-KINTANAR, MD, FPCR, FCTMRISP
RADIOLOGIST



Rhoby U. Orata M.D., FAFN, FPCS
Neurosurgeon and Spinal Diseases

ARMANDO L. GARCIA HOSPITAL
Rizal St., Angeles City
Room 401 - Friday: 1.00pm to 4.00pm

**ANGELES UNIVERSITY
FOUNDATION MEDICAL CENTER**
Room 109 - Friday: 9.00am to 12.00nn

**ST. RAPHAEL FOUNDATION
AND MEDICAL CENTER, INC.**
Room 106 - Friday: 4.00pm to 6.00pm

Hospital Affiliations:

Angeles University Foundation Medical Center, Armando L. Garcia Hospital,
St. Raphael Foundation and Medical Center, Inc., Our Lady of Mt. Carmel Medical Center,
St. Catherine of Alexandria Foundation and Medical Center

PATIENT: Irene de guzman Date: May 30
Address: porac Pampanga Age 43 Sex: F

Rx (Costing for operation)

rp Shuntin

PF \$ 450.00


Hospital \$ 200.00

SEC. TINA SANCHEZ
Mobile Nos.:
0945-182-1442

Orata
Rhoby U. Orata M.D., FAFN, FPCS
Lic. No. #91723
PTR No. _____



Republic of the Philippines
Province of Pampanga
Municipality of Porac
BARANGAY PIO



Office of the Punong Barangay

Sangguniang Barangay

HON. MELCHOR CANLAPAN
Punong Barangay

Kagawad

HON. MARCELINA G. DELA CRUZ
Health and Sanitation

HON. VINER M. DIMALANTA
Livelihood and Employment

HON. MARIAN L. CURA
Education

HON. CELSO D. DIMALANTA
Public Works and Infrastructure

HON. ENRIQUE M. DAVID
Peace and Order

HON. JOVIC D. SANTIAGO
Agriculture and Waste Management

HON. EDUARDO M. CANLAPAN
Appropriation/Ways and Means

HON. JOEL RED II M. LISING
S.K. Chairperson/Sports

KAREN JOY O. MANALANSAN
Treasurer

JANICE R. MIRANDA
Secretary

CERTIFICATE OF INDIGENCY

To Whom It May Concern:

This is to certify that IRENE MALIG DE GUZMAN
☐single ☐married ☒widow/widower, 43 years old,
Filipino and a resident of this barangay with postal
address at BK-15 Lot 91 Model Community Pio, Porac,
Pampanga.

It is further certified that the subject person
belongs to the indigent families in this barangay.

This certification is being issued upon request
of the above-named person for Financial Assistance
purposes.

Issued this 19th day of May, 2025
at Barangay Pio, Porac, Pampanga.

Certified by:

HON. MELCHOR CANLAPAN
Punong Barangay

This is not intended for photocopying

Not Valid Without the Official Seal